

PennHIP Report

Referring Veterinarian: Dr Jane Barber	Clinic Name: Veterinary Specialties Hospital at the Lake
Email: info@vetspecslkn.com	Clinic Address: 1675 Mollys Backbone Road Sherrills Ford, NC 28673
	Phone:
	Fax:

Patient Information

Client: Fish, Jacki	Tattoo Num:
Patient Name: Riggs	Patient ID: 18778
Reg. Name:	Registration Num:
PennHIP Num: 198054	Microchip Num: 900235000191832
Species: Canine	Breed: GOLDENDOODLE CROSS
Date of Birth: 30 Dec 2022	Age: 14 months
Sex: Male	Weight: 60 lbs/27.2 kgs
Date of Study: 19 Feb 2024	Date Submitted: 21 Feb 2024
Date of Report: 21 Feb 2024	

Findings

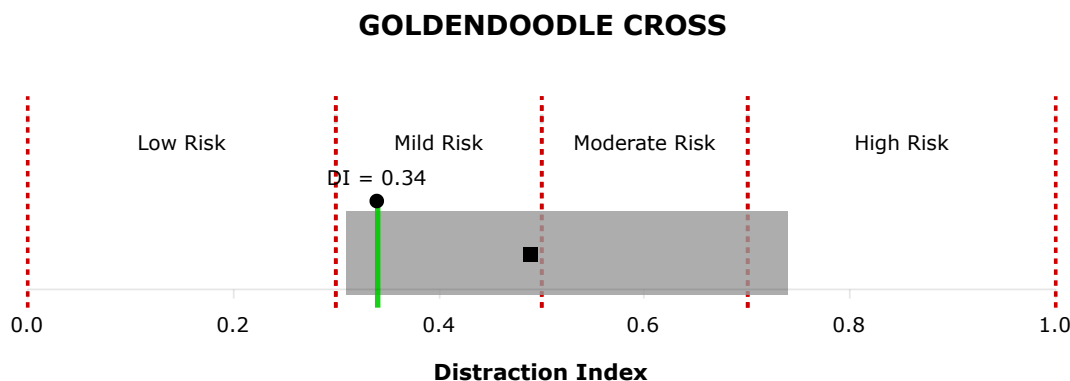
Distraction Index (DI): Right DI = 0.34, Left DI = 0.33.
Osteoarthritis (OA): No radiographic evidence of OA for either hip.
Cavitation/Other Findings: No cavitation present.

Interpretation

Distraction Index (DI): The laxity ranking is based on the hip with the greater laxity (larger DI). In this case the DI used is 0.34.

OA Risk Category: The DI is between 0.31 and 0.49. This patient is at mild risk for hip OA.

Distraction Index Chart:



BREED STATISTICS: This interpretation is based on a cross-section of 3549 canine patients of the GOLDENDOODLE CROSS breed in the AIS PennHIP database. The gray strip represents the central 90% range of DIs (0.31 - 0.74) for the breed. The breed average DI is 0.49 (solid square). The patient DI is the solid circle (0.34).

SUMMARY: The degree of laxity (DI = 0.34) falls within the central 90% range of DIs for the breed. This amount of hip laxity places the hip at a mild risk to develop hip OA. **No radiographic evidence of OA for either hip.**

